

CASE REPORT

A Case of Idiopathic Subglottic and Bilateral Bronchial Stenosis

Ümit Aydoğmuş¹, Gökhan Yuncu², Figen Türk¹

¹Department of Chest Surgery, Pamukkale University Faculty of Medicine, Denizli, Turkey

²Department of Chest Surgery, Liv Hospital, İstanbul, Turkey

Abstract

Subglottic stenosis is rarely idiopathic. In this case report, a 40-year-old female patient presented with subglottic stenosis with an unidentified etiology along with bilateral bronchial stenosis. Hoarseness arose in the last 4 years in this patient, who was undergoing treatment because of asthma for 13 years. Her physical examination revealed the presence of bilateral rhonci. Her tomography analysis revealed tracheal stenosis in a 2-cm segment at the C6-7 level. Her bronchoscopy analysis revealed subglottic stenosis. White plaques were observed in the entire tracheobronchial tree; biopsy was performed and lavage was taken. Samples were sent for pathological and microbiological examinations. Stenosis in the bronchial system was clear in the left main bronchus entry and at the right intermediate bronchus level. Dilatation was performed. Chronic active inflammation and squamous hyperplasia were observed in the pathology of the biopsies. Growth did not occur in tuberculosis and nonspecific cultures. Reflux was not present in the gastrointestinal system examination. All serological and rheumatologic examinations performed were normal. Idiopathic subglottic stenosis is exceedingly rare. Bronchial system stenosis accompanying idiopathic tracheal stenosis is even rarer, and its treatment is difficult.

KEY WORDS: Bronchial stenosis, idiopathic tracheal stenosis, idiopathic bronchial stenosis, subglottic stenosis, tracheal stenosis

Received: 06.01.2015

Accepted: 19.03.2015

Available Online Date: 03.12.2015

INTRODUCTION

The general causes of tracheal stenosis are intubation, tracheostomy, chemical or basic damage, and trauma. Rarer, inflammatory diseases such as Wegener's granulomatosis (WG), connective tissue diseases, and sarcoidosis can play roles in the etiopathogenesis. When all these causes are excluded, the diagnosis is idiopathic subglottic stenosis (ISS) [1]. ISS is a very rare disease, more commonly observed in women. In this study, an ISS case that constituted a difficulty in treatment because of diffuse stenosis in both bronchial systems accompanying subglottic stenosis is presented.

CASE PRESENTATION

A 40-year-old female patient who was undergoing treatment for asthma underwent appendectomy 9 years ago. Prolonged intubation was not present. Hoarseness started in the last 4 years, nose bleeding occurred 2 weeks ago, and she was evaluated by an ear, nose, and throat expert. Sinusitis and nasal crusts were observed in the patient. After a recurrence of nose bleeding, indirect laryngoscopy was performed, and "stenosis in the subglottic area" was observed and she was directed to our polyclinic.

Bilateral rhonchus and stridor were present in her physical examination. Sedimentation and C-reactive protein values were normal in her blood analyses. There were no features in her chest radiography.

In the respiratory function test, FVC was measured as 3.48 l (71%), FEV₁ as 3.01 l (65%), and FEV₁/FVC as 87%. In her cervical and thoracic computed tomography, tracheal stenosis was observed in the narrowest part of an approximately 2-cm segment at the C6-7 level, with a coronal diameter of 7.7 mm and a sagittal diameter of 12.1 mm (Figure 1). Endobronchial lesion was not detected. Subsegmental linear atelectasis appearance was present in the lower left pulmonary lobe.

Fiberoptic bronchoscopy was performed to the patient with a provisional diagnosis of subglottic stenosis, as a way of planning prior to the surgical intervention. Stenosis that proceeded for subglottic 2-cm segment was observed in the

This case report was presented in the TUSAD 36th National Congress (SOLUNUM 2015, October 15–19, 2014, Çeşme, İzmir, Turkey)



Address for Correspondence: Ümit Aydoğmuş, Pamukkale Üniversitesi Tıp Fakültesi, Göğüs Hastalıkları Anabilim Dalı, Denizli, Türkiye Phone: +90 258 444 07 28 E-mail: mdaydogmus@yahoo.com
©Copyright 2015 by Turkish Thoracic Society - Available online at www.toraks.dergisi.org

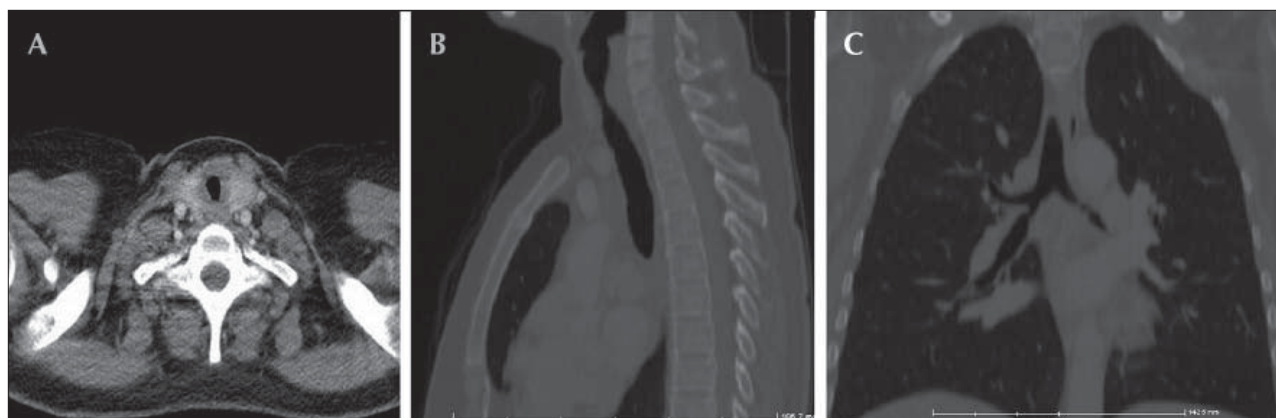


Figure 1. Thoracic CT sections. (a) Stenosis in the subglottic region in the transverse section. (b) Stenosis in the sagittal section is observed to be on a segment that is approximately 2 cm long. (c) Stenosis is observed in the left main bronchus in the coronal section.

fiberoptic bronchoscopy (Figure 2). Diffuse white plaques that occasionally caused webs were observed in the entire tracheobronchial tree. Stenosis in the bronchial system was clear in the left main bronchus entry and at the right intermediate bronchus level (Figure 2). Because of diffuse stenosis, surgical intervention was abandoned, and rigid bronchoscopy was performed in the same session. Biopsy was performed in stenosis areas and lavage was taken. Samples were sent for pathological and microbiological examinations. Dilatation was performed upon noticing, during rigid bronchoscopy, that the stenosis was not very stiff. The pathology of biopsy and lavage was reported as “chronic active inflammation and squamous hyperplasia.” Growth did not occur in tuberculosis and nonspecific cultures. Mycobacteria polymerase chain reaction (PCR) studies were negative. Microorganisms were not observed in Gram staining, and fungal spores and hyphae were not observed in periodic acid-Schiff staining.

When the tomography of the patient was uploaded to the three-dimensional software and retrospectively re-examined, stenosis was observed in the bronchial systems as well in the coronal sections (Figure 1c).

Reflux was not present in the gastrointestinal system examination. Serological and rheumatologic examinations [anti-nuclear antibody (ANA)= negative, cytoplasmic anti-neutrophil antibody (c-ANCA)= negative] did not return any pathological findings.

The complaints of the patient with respect to shortness of breath increased 6 months after bronchoscopic dilatation, and dilatation was performed again with rigid bronchoscopy, and mitomycin C attachment was performed. The patient developed complaint of hemoptysis 15 days after the surgery, and she was hospitalized and followed up for 2 days. During hospitalization and later follow-ups, hemoptysis complaints did not arise. The patient is being followed up without symptoms on the 8th month of the 2nd bronchoscopic dilatation. Written consents for every intervention performed were obtained from the patient. The obtained written consents included the potential scientific and educational use of the findings and images regarding her disease.

DISCUSSION

The most frequent causes of tracheobronchial system stenoses are intubation and tracheostomy. ISS is quite rare. In the study of Rubikas et al. [2] consisting of 75 laryngotracheal patients, only one patient’s diagnosis was ISS, and the cause of stenosis of 71 patients was intubation. The physiopathology is not known in ISS; however, some authors claimed that gastroesophageal reflux, chronic coughing, and abnormal estrogen response can have influences [3]. On the other hand, its relationship with WG is emphasized in many studies and cases. It is reported that as much as 49% of the patients are diagnosed with ISS because of the absence of WG findings and symptoms [4]. There are even cases that were diagnosed as WG 20 years after the ISS diagnosis [5]. The case was examined for WG, and WG diagnosis was excluded. Nevertheless, her follow up continues in light of the literature.

The treatment of ISS is controversial because it is rarely seen and its physiopathology is unclear. Surgical treatment is still the first treatment choice, with success rates as high as 90% in subglottic stenoses associated with a benign factor [6]. Marcillo et al. [3] reported a 97% success rate with surgical correction in a study consisting of 64 cases with diagnoses of ISS. Endoscopic treatments are reported as good for palliation and as progressing with frequent recurrences in the long run [7]. There are also authors, most of which report achieving sufficient results with endoscopic treatment [8]. The type the endoscopic treatment methods to be performed is a controversy. Mitomycin C application is frequently recommended in endoscopic applications [6]. Stent applications added to dilatation will yield longer palliation in the patient, and it can establish patient’s comfort without the need of tracheostomy or more invasive processes [9]. Radiological and clinical findings of the patient made us consider ISS; therefore, surgical treatment was planned following bronchoscopic evaluation. However, bronchoscopy revealed that the patient not only had ISS but also bronchial stenoses. She therefore differed from the cases previously reported in the literature. Surgical treatment was not possible in our patient, and we performed bronchoscopic dilatation in the first admittance. In the second admittance, mitomycin C was administered alongside dilatation. Mitomycin C is an antineoplastic agent

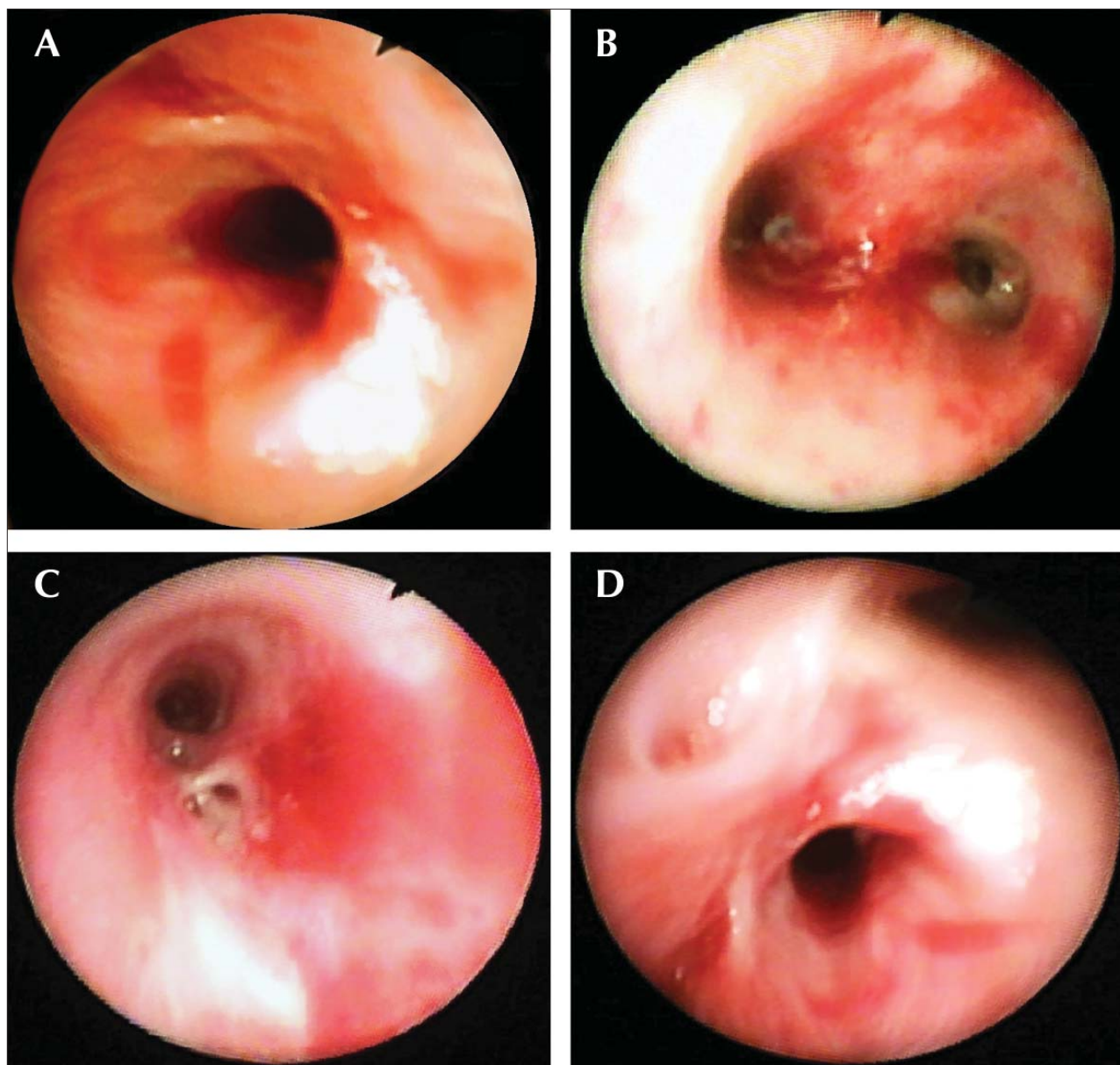


Figure 2. Bronchoscopic images. (a) Stenosis in the subglottic level. (b) Appearance in the carina level. (c) Stenosis in the left main bronchus. (d) Stenosis in the right intermediate bronchus.

that inhibits fibroblast proliferation and modulates wound healing [10]. Good results of its application as a support for endoscopic treatment in trachea stenoses are reported [10]. The case was particularly observed to benefit from the second dilatation (one where mitomycin C was performed). In the retrospective, radiological examination, in addition to the initial evaluation of radiologists, stenoses are observed in the left main bronchus as well in the coronal sections (Figure 1c). We maintain that although the treatment plan of tracheal diseases is being formed, it is crucial that the detailed radiological examinations are conducted by radiology experts who are experienced in this subject.

Surgical correction is the first choice in cases of airway stenoses associated with a benign factor, if an emergency response is not required [6,8]. This case was not suitable for surgical treatment because of diffuse airway involvement.

Dilatation is an important treatment choice in patients with submucosal or extrinsic lesions where curative surgery is not possible [8]. Similarly, dilatation is the first choice in cases with submucosal or extrinsic lesions who require an emergency response, and stent is recommended in suitable patients [8]. Mechanical dilatation can provide sufficient treatment, particularly in cases with web-style ISS [1]. Bronchoscopic, radiological, and pathological findings of the case made us consider a submucosal-type stenosis, and no finding was detected regarding cartilaginous type-stenosis. Therefore, we maintain that the case benefited, at least partially, from dilatation. Because of diffuse airway stenosis and the complexity of stenosis localizations, we initially did not consider stent application in our case. Stent application can be considered as a treatment option if stenosis recurs in our patient who is being followed up. In cases with cartilaginous-type stenosis or with an exophytic lesion, curating with

dilatation and endobronchial treatment modalities (laser, electrocautery, cryotherapy, photodynamic treatment etc.) are recommended [8]. Furthermore, surgical treatment procedures can be performed depending on the etiological and pathological cause [2]. Endobronchial treatment modalities (preferably laser, because it is responsible for less mucosal damage) can be used in cases with submucosal stenosis in whom dilatation cannot be achieved via conventional methods (such as balloon and bougienage) [8]. Endobronchial treatment modalities were not required in our case where sufficient airway patency was established via mechanical dilatation. Stent was not considered because of the diffusiveness of the lesions.

Idiopathic subglottic stenosis is a rare condition, and there is no consensus regarding its treatment. Because of its slow progression, patients can undergo asthma treatment by mistake for a long time. We tried to administer endoscopic treatment in our case that differed from other ISSs due to diffuse stenosis in the tracheobronchial system. We assume that, in tracheobronchial system stenoses, one must develop a treatment strategy on a case-by-case basis and choose a treatment that is specific to the case.

Informed Consent: Written informed consent was obtained from the patient who participated in this case.

Peer-review: Externally peer-reviewed.

Author Contributions: Concept - Ü.A., G.Y.; Design - Ü.A., F.T.; Supervision - G.Y.; Data Collection and/or Processing - Ü.A.; Analysis and/or Interpretation - Ü.A., F.T., G.Y.; Literature Review - Ü.A., F.T.; Writer - Ü.A.; Critical Review - F.T., G.Y.

Conflict of Interest: No conflict of interest was declared by the authors.

Financial Disclosure: The authors declared that this study has received no financial support.

REFERENCES

1. Perotin JM, Jeanfaivre T, Thibout Y, et al. Endoscopic management of idiopathic tracheal stenosis. *Ann Thorac Surg* 2011;92:297-301. [\[CrossRef\]](#)
2. Rubikas R, Matukaiyte I, Jelisiejovas JJ, Rackauskas M. Surgical treatment of non-malignant laryngotracheal stenosis. *Eur Arch Otorhinolaryngol* 2014;271:2481-7. [\[CrossRef\]](#)
3. Morcillo A, Wins R, Gómez-Caro A, et al. Single-staged laryngotracheal reconstruction for idiopathic tracheal stenosis. *Ann Thorac Surg* 2013;95:433-9. [\[CrossRef\]](#)
4. Langford CA, Sneller MC, Hallahan CW, et al. Clinical features and therapeutic management of subglottic stenosis in patients with Wegener's granulomatosis. *Arthritis Rheum* 1996;39:1754-60. [\[CrossRef\]](#)
5. Peters JE, Salama AD, Ind PW. Wegener's granulomatosis presenting as acute systemic vasculitis following 20 years of limited tracheobronchial disease. *J Laryngol Otol* 2009;123:1375-7. [\[CrossRef\]](#)
6. Ortiz R, Dominguez E, De La Torre C, et al. Early endoscopic dilation and mitomycin application in the treatment of acquired tracheal stenosis. *Eur J Pediatr Surg* 2014;24:39-45. [\[CrossRef\]](#)
7. Ashiku SK, Kuzucu A, Grillo HC, et al. Idiopathic laryngotracheal stenosis: effective definitive treatment with laryngotracheal resection. *J Thorac Cardiovasc Surg* 2004;127:99-107. [\[CrossRef\]](#)
8. Ernst A, Feller-Kopman D, Becker HD, Mehta AC. Central airway obstruction. *Am J Respir Crit Care Med* 2004;169:1278-97. [\[CrossRef\]](#)
9. Sökücü SN, Karasulu L, Altın S, et al. A Wegener granulomatosis case presenting with acute laryngotracheal airway obstruction. *Turk Thorac J* 2011;12:32-5. [\[CrossRef\]](#)
10. Rahbar R, Shapshay SM, Healy GB. Mitomycin: Effects on laryngeal and tracheal stenosis, benefits, and complications. *Ann Otol Rhinol Laryngol* 2001;110:1-6. [\[CrossRef\]](#)